



PRESENTING CLINICAL SIGNS

History: New murmur. One pound weight loss. BNP >1200. T4 normal.

DATE

1/18/23

ECHOCARDIOGRAPHIC FINDINGS

2D, M-mode, and Doppler study.

PERFORMED BY:

Tom McNeill

Left atrial size is normal. The mitral valve is normal. There is mild left ventricular hypertrophy. Left ventricular internal dimensions are normal. Left ventricular systolic function is hyperdynamic. The aorta and aortic valve are normal. Right atrial and right ventricular dimensions are normal. The tricuspid valve is normal. The pulmonary artery and pulmonic valve are normal. No shunting lesions are visualized. No pericardial effusion or cardiac masses are seen.

INTERPRETED BY

Keith Blass, DVM,
MS, DACVIM
(Cardiology)

LA/Ao - 1.42
IVSd - 6.0 mm
LVPWd - 6.0 mm
LVIDd - 15.8 mm
LVIDs - 6.4 mm
FS - 59.5%
LVOT - 0.69 m/s
RVOT - 0.77 m/s

PATIENT

Little Klein

ASSESSMENT/RECOMMENDATIONS

SPECIES

Feline

This examination demonstrates mild hypertrophy of Little's left ventricular walls, with differentials for this finding including hypertrophic cardiomyopathy (HCM) and systemic hypertension. The hemodynamic effects of the hypertrophy appear to be mild, as Little does not have secondary dilation of his left atrium, indicating that his current risk for the development of congestive heart failure and/or thromboembolic disease appears to be low.

BREED

No reason for Little's weight loss is appreciated in this exam.

DSH

While a definitive reason for Little's murmur was not identified, it's likely that his murmur is functional/innocent in nature, as no flow abnormalities that could result in the development of a pathologic murmur were appreciated in the image set.

SEX

A blood pressure measurement is recommended.

MN

No therapy is recommended based on this exam.

AGE

12 y

A recheck echocardiogram is recommended in 6-9 months, sooner if new clinical signs compatible with cardiac dysfunction (ex. labored breathing, collapse, limb paralysis) develop.

WEIGHT

11.7 lb

HOSPITAL NAME

SVS Imaging CT

REFERRING VET

Dr. Metzger



DATE

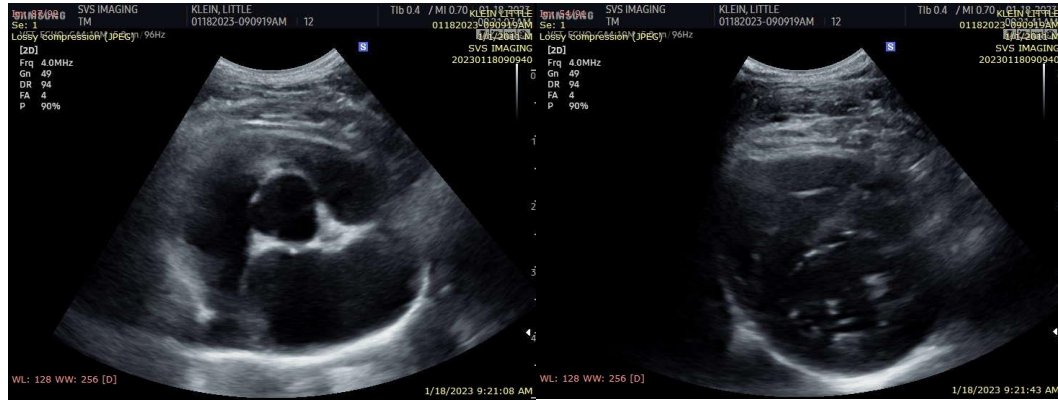
1/18/23

PERFORMED BY:

Tom McNeill

INTERPRETED BY

Keith Blass, DVM,
MS, DACVIM
(Cardiology)



The information and recommendations provided are based on the images presented by the referring veterinarian. No evaluation can be communicated regarding pathology that was not visible in the image/video clips provided.

Thank you for this referral. If the clinical or image interpretation does not parallel your findings or if I can be of any further assistance please contact me.

PATIENT

Little Klein

Keith Blass, DVM, MS, DACVIM (Cardiology)
KeithBlass@gmail.com
631-804-5754

SPECIES

Feline

BREED

DSH

SEX

MN

AGE

12 y

WEIGHT

11.7 lb

HOSPITAL NAME

SVS Imaging CT

REFERRING VET

Dr. Metzger